

Structural Study of Prepuce in Hypospadias—Does Topical Treatment With Testosterone Produce Alterations in Prepuce Vascularization?

André Netto Bastos, Leonardo Resende Souza Oliveira, Carlos Eduardo Prata Fernandes Ferrarez, André Avarese de Figueiredo, Luciano Alves Favorito and Jose Murillo Bastos Netto*

From the Federal University of Juiz de Fora and Urogenital Research Unit, Rio de Janeiro State University, Rio de Janeiro, Brazil

Abbreviation and Acronym

vWF = von Willebrand's factor

Study received institutional review committee and parental approval.

* Correspondence: Av. Rio Branco, 2985/sl. 605, Juiz de Fora-MG, Brazil, 36010012 (telephone: 55(32) 3218-9899; FAX: 55(32)3218-9899; e-mail: jmbnetto@uopedjf.com.br).

Purpose: Androgen stimulation before hypospadias surgery has resulted in increased penile size, fewer complications and improved cosmesis, and suggests increased neovascularization. To our knowledge the real effect on neovascularization remains to be proved. We studied the histological effects of testosterone on neovascularization.

Materials and Methods: A total of 26 boys with hypospadias were randomly allocated to 2 groups before surgical correction. Group 1 did not receive any treatment and group 2 received 1% testosterone propionate ointment twice daily for 30 days before surgery. During the surgical procedure a fragment of prepuce was excised and prepared for histological evaluation. The number and volume density of blood vessels were determined by labeling for von Willebrand's factor. Blood vessel quantification as volume density was done using a video microscopy system with a superimposed cycloid arch test system.

Results: The groups were similar in age and hypospadias classification. Testosterone treated prepuces (group 2) had an increased absolute number of blood vessels (mean \pm SD 8.5 ± 1.3 vs 4.8 ± 1.8 vessels per field) and increased blood vessel volume density (mean $50.5\% \pm 7.8\%$ vs $24.8\% \pm 8.6\%$ vessels per point) (each $p < 0.001$) compared to those in untreated patients (group 1).

Conclusions: The use of 1% testosterone propionate ointment before hypospadias surgery produces neovascularization in absolute numbers and in volume density.

Key Words: urethra; neovascularization, physiologic; hypospadias; testosterone; foreskin

HYPOSPADIAS is a common congenital defect and surgical correction, even in experienced hands, is prone to complications. A cosmetically adequate surgical outcome is often not attained with 25% of patients reporting dissatisfaction with the cosmetic appearance of the penis.¹ Androgen stimulation with testosterone, dihydrotestosterone or human chorionic gonadotropin has been used to improve the cosmesis and decrease the complications of hypospa-

dias surgery since it temporarily increases the penis and makes surgical correction easier.² Besides a penile increase other studies have shown decreased chordee, corpus spongiosum thickening and decreased hypospadias.³ Chalapathi et al found no differences in penile size, testosterone side effects and serum testosterone when comparing topical to intramuscular testosterone.⁴

Nevertheless, the testosterone effects that lead to better postoperative

results are yet to be fully understood. Histology of the preoperatively androgen treated prepuce, especially targeting tissue vascularization, is paramount once greater blood flow decreases fibrous tissue formation and inflammation, decreases postoperative complications and improves cicatrization through better cutaneous nutrition and oxygenation.⁵

We analyzed the histological effects of topic testosterone applied before hypospadias surgery on preputial vascularization.

MATERIALS AND METHODS

The current study received institutional review committee and parental approval. It was done in accordance with the ethical standards of the responsible institutional committee on human experimentation.

We studied untreated prepubescent children with hypospadias who did not present with any other genital or endocrine condition. After surgery the children were divided at random using the Research Randomizer (www.randomizer.org) into 2 groups. Group 1 with no testosterone included 13 children who did not receive any preoperative hormonal treatment. Group 2 with testosterone included 13 children who received 1% testosterone propionate ointment for use on the whole penis twice daily for 30 days before hypospadias surgical correction. Parents were instructed to use the same amount each time.

During the surgical procedure a small fragment of prepuce (about 1.5 cm²) containing the inner and outer surfaces was removed. The preputial fragment was fixed in 10% buffered formalin and routinely processed for paraffin embedding with 4 μm thick sections obtained at 200 μm intervals.^{6,7} The material was stained with hematoxylin and eosin for histological examination. The pathologist evaluated the preputial fragment as a spiral including 10 random fields in which the inner and outer surfaces of the skin were examined as 1 piece.

The streptavidin-biotin-peroxidase method was used for immunohistochemical staining for vWf.⁸ Three randomly chosen microscopic fields at 200× magnification were photographed. The absolute number of blood vessels

Hypospadias classification in groups 1 and 2

Hypospadias	No. Group 1	No. Group 2
Glandular	2	2
Coronal	4	5
Subcoronal	4	3
Penile:		
Mid	2	2
Posterior	1	1
Totals	13	13

per field was counted and the mean number of blood vessels per field was determined. Using a microscope adapted video system, including a DMR DMRBE microscope (Leica, Exton, Pennsylvania), a Prior® video camera and a Trinitron® monitor, 3 randomly chosen 200× fields were photographed. Cycloid points were superimposed on the images. The vessels that touched the cycloid points were counted and those that did not touch were discarded (fig. 1, A). Vascular volume density (VV) was then determined using the formula, $VV = PP/TP$, where PP corresponds to the number of vessels touching each 1 of the 16 cycloid points and TP corresponds to the total number of points (16).^{9,10}

The means were statistically compared using the unpaired t test with Prism® software. Results were considered statistically significant at $p < 0.05$.

RESULTS

The 2 groups were homogeneous according to mean age and hypospadias classification (see table). In group 1 mean ± SD age was 67.5 ± 48.1 months (range 4 to 120) and in group 2 it was 41.3 ± 36.5 months (range 12 to 120). Analysis of immunohistochemical staining for vWF revealed a significant increase in the absolute number of preputial blood vessels in group 2 compared to those in group 1 (mean 8.5 ± 1.3 vs 4.8 ± 1.8 vessels per field, $p < 0.001$, figs. 1, B and C and 2, A). Structural

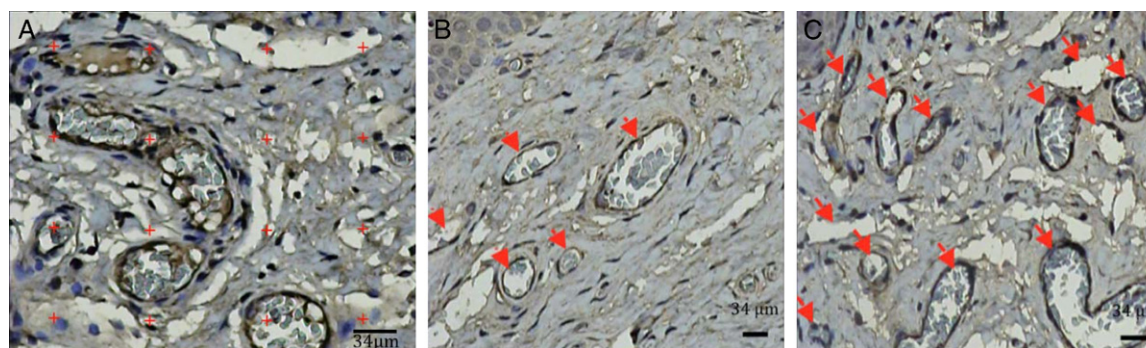


Figure 1. Photomicrographs show preputial morphometric analysis. A, blood vessel quantification by 16 cycloid points (plus marks) in microscopic field in group 1 patient without testosterone at 69 months. B and C, histological view of quantification of blood vessels per field (arrows) at 16 months. B, group 1 patients without testosterone. C, group 2 patient with testosterone. vWF, reduced from ×200.

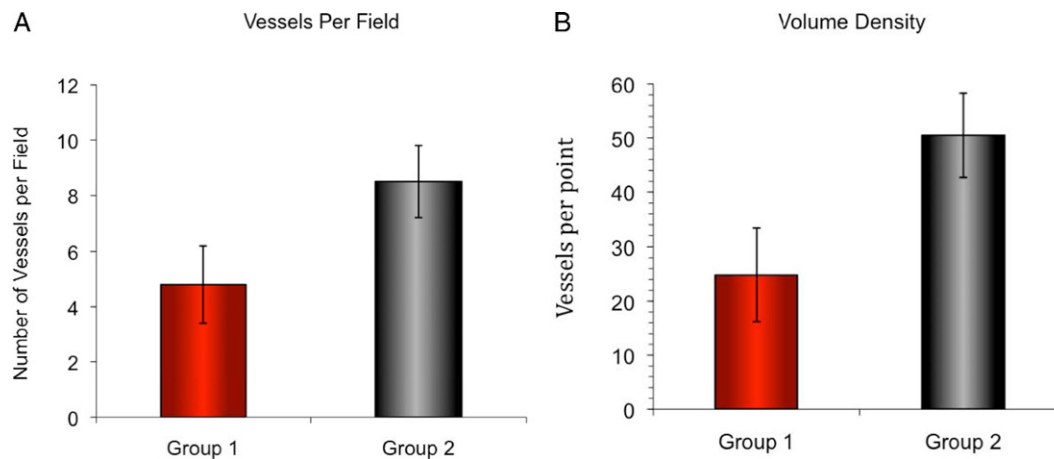


Figure 2. There was significant increase in absolute number of preputial blood vessels in group 2 with vs group 1 without testosterone (8.5 ± 1.3 vs 4.8 ± 1.8 vessels per field, $p < 0.001$). A, absolute number of preputial blood vessels as vessels per field. B, volume density as vessels per point.

analysis using the cycloid point method showed a statistically significant increase in blood vessel volume density in group 2 compared to that in group 1 ($50.5\% \pm 7.8\%$ vs $24.8\% \pm 8.6\%$ vessels per point, $p < 0.001$, *fig. 2, B*).

DISCUSSION

Hypospadias correction is a challenging surgery for the urologist since it demands high operative skills, experience, and knowledge of the several techniques described and the quality of the available penile tissue. Postoperative outcome depends on surgeon experience, site of the urethral meatus, degree of penile curvature, urethral plate width and quality, and the amount and quality of the foreskin available for correction.^{11,12} Different degrees of preoperative fibrosis may be an additional difficulty leading to unfavorable surgical results since poor quality skin may result in impaired cicatrization.¹²

Topical or intramuscular preoperative testosterone favorably impacts the surgical results, decreasing the number of postoperative complications.^{13,14} This is chiefly due to penile lengthening and widening along with increased vascularization.^{4,15} Although testosterone use is well accepted by many pediatric urologists, there is still room for questioning its real value for hypospadias preoperatively. In 2010 Gorduz et al reported more complications in patients with proximal hypospadias after preoperative androgen stimulation, especially in those operated on less than 3 months after hormone use.¹⁶

Little investigation has been done of the real effects of androgen stimulation on preputial tissue. Most reports that refer to better vascularization are based on an empirical view with no histological study of its real effect on the prepuce. Studies in

other tissues are controversial. In a study of oral mucosal healing England et al speculated that testosterone may impact the proliferative phase of healing, which involves immune processes such as re-epithelialization and angiogenesis.¹⁷ Other studies show a deleterious effect of endogenous testosterone on the healing process, especially in the elderly population,^{18–20} with better healing achieved by estrogen stimulation.^{18,19} In experimental models in mice it was noted that accelerated and better healing occurred after endogenous androgen blockade by castration.²⁰

On the other hand, androgen activation and deactivation are mainly intracellular events that can differ among cell types and among cells at different locations. This statement reinforces the need for more studies of penile tissue, which has a great correlation with hormonal stimulation. Using immunohistochemical staining we found a trend toward more intensive marking in group 1 without testosterone. This may have been due to the occupation of androgen receptors by the testosterone applied on the penis in group 2. We did not separate the inner and outer foreskin. Although differences may be present between these 2 types of preputial skin, we found no study in the literature to support this hypothesis and justify a different evaluation of the inner and the outer foreskin.

Better vascularization is important in any repair surgery, especially that requiring a number of sutures whose tightness is essential if urine leaks are to be avoided. Besides the sutures, cutaneous flap rotation and the use of cutaneous grafts from the oral mucosa and other sites are often necessary. Thus, vascularization is of major importance. Adequately nourished and oxygenated skin is more

prone to better cicatrization,⁶ leading to a better surgical scar with fewer failures and complications.⁵

To evaluate neovascularization we used vWF, which is a recognized and efficient marker for this purpose. vWF is a glycoprotein produced uniquely by endothelial cells and megakaryocytes. The rapidity, objectivity, sensitivity and specificity of this technique make it suitable for routine clinical application to identify angiogenesis.²¹

We noted increased vWF labeling in the prepuce of boys with hypospadias who received topical testosterone. This is an important finding when considering the inverse relation between vascularization, and the development of inflammation and fibrosis. Dodge-Khatami et al used tracheal grafts to repair tracheal stenosis and observed that when endothelial vascular growth factor was used before transplantation, there was higher vascular density, and less submucosal fibrosis and inflammation.²² This shows that greater blood flow can decrease fibrosis and inflammation. Another study of endothelial vascular growth factor in a progressive renal failure (remnant kidney) model revealed increased endothelial cellular proliferation and reduced interstitial collagen deposition. These findings point to hypoxia as a powerful stimulant of collagen synthesis and the ability of increased blood flow to decrease these effects.¹⁶ These studies suggest that better vascularized tissue is prone to better healing with less fibrosis. As shown in this study, topical testosterone increases vascularization. According to the studies described, this may enhance scar formation and postoperative cosmesis. On the other hand, to our knowledge we still do not know whether exogenous hormone is deleterious to the healing process.

Although we noted no local complication, such as skin reaction, allergy or pain, with testosterone use on the penis, topical use has the disadvantage of family control of the dose and the frequency of ointment application during the prescription period. In

this study it was prescribed to be applied twice daily during 30 days. However, since we found statistical differences between the groups, we conclude that the patients applied the ointment themselves.

Our results reveal that topical 1% testosterone propionate stimulated angiogenesis, leading to significantly increased vascular volume density and the number of blood vessels. Since tissues with vessels of wider caliber or an increased extracellular matrix (even due to increased collagen) may have a decreased number of vessels per field, we also used cycloid arches for this counting. In this way vascular volume density was determined and we noted an increase in vessel number and total blood vessel volume, confirming vascular neof ormation. Our findings are in accordance with the literature on improving tissue vascularization with testosterone.⁴

We did not measure blood levels of testosterone before and after hormone stimulation. Although we think that these findings would have enriched our data, we believe that they were not necessary in this study since it is known that testosterone causes foreskin alterations.^{12,23} This was also demonstrated in our series as the induction of increased preputial neovascularization. The final results of surgery were not compared. Further research is needed to evaluate these results as well as other effects of testosterone stimulation before hypospadias surgery.

CONCLUSIONS

The use of 1% testosterone propionate ointment before hypospadias surgery produces neovascularization, increasing the absolute number of vessels and blood vessel volume density. This finding may explain the better postoperative outcomes due to better oxygenation of the cells involved in the healing process.

REFERENCES

- Mureau MA, Slijper FM, Nijman RJ et al: Psychosexual adjustment of children and adolescents after different types of hypospadias surgery: a norm-related study. *J Urol* 1995; **154**: 1902.
- Monfort G and Lucas C: Dehydrotestosterone penile stimulation in hypospadias surgery. *Eur Urol* 1982; **8**: 201.
- Koff SA and Jayanthi VR: HCG pretreatment of proximal hypospadias in infancy decreases the severity of hypospadias and chordee. *J Urol* 1999; **162**: 1435.
- Chalapati G, Rao KL, Chowdhary SK et al: Testosterone therapy in microphallic hypospadias: topical or parenteral? *J Pediatr Surg* 2003; **38**: 221.
- Dinar S, Agir H, Sen C et al: C. Effects of hyperbaric oxygen therapy on fibrovascular ingrowth in porous polyethylene blocks implanted under burn scar tissue: an experimental study. *Burns* 2008; **34**: 467.
- Ichioka S, Ando T, Shibata M et al: T. Oxygen consumption of keloids and hypertrophic scars. *Ann Plast Surg* 2008; **60**: 194.
- Artacho-Pérua E and Roldán-Villalobos R: Estimation of capillary length density in skeletal muscle by unbiased stereological methods: II. Use of vertical slices of unknown thickness. *Anat Rec* 1995; **241**: 345.
- Zanetta L, Marcus SG, Vasile J et al: Expression of Von Willebrand factor, an endothelial cell marker, is up-regulated by angiogenesis factors: a potential method for objective assessment of tumor angiogenesis. *Int J Cancer* 2000; **85**: 281.
- Amenábar JM, Martins GB, Cherubini K et al: Comparison between semi-automated segmentation and manual point-counting methods for quantitative analysis of histological sections. *J Oral Sci* 2006; **48**: 139.

10. Kockx MM, Knaapen MWM, Bortier HE et al: Vascular remodeling in varicose veins. *J Vasc Diseases* 1998; **49**: 871.
11. Mouriquand PDE and Mure PY: Current concepts in hypospadiology. *BJU Int* 2004; **93**: 26.
12. Stern JM, Chen J, Peters SB et al: Testosterone treatment of human foreskin in a novel transplant model. *Urology* 2004; **63**: 999.
13. Sakakibara N, Nonomura K, Koyanagi T et al: Use of testosterone ointment before hypospadias repair. *Urol Int* 1991; **4**: 40.
14. Kaya C, Bektic J, Radmayr C et al: The efficacy of dihydrotestosterone transdermal gel before primary hypospadias surgery: a prospective, controlled, randomized study. *J Urol* 2008; **179**: 684.
15. Franck-Lissbrant I, Häggström S, Damber JE et al: Testosterone stimulates angiogenesis and vascular regrowth in the ventral prostate in castrated adult rats. *Endocrinology* 1998; **139**: 451.
16. Gorduza DB, Gay CL, de Mattos E Silva E et al: Does androgen stimulation prior to hypospadias surgery increase the rate of healing complications? A preliminary report. *J Pediatr Urol* 2010; Epub ahead of print.
17. England CG, Sabzehei B and Marucha PT: Sex hormones and mucosal wound healing. *Brain Behav Immunol* 2009; **23**: 629.
18. Gilliver SC, Ruckshanthi JPD, Hardman MJ et al: 5 α -Dihydrotestosterone (DHT) retards wound closure by inhibiting re-epithelialization. *J Pathol* 2009; **217**: 73.
19. Gilliver SC, Ashworth JJ and Ashcroft GS: The hormonal regulation of cutaneous wound healing. *Clin Dermatol* 2007; **25**: 56.
20. Ashcroft GS and Mills SJ: Androgen receptor-mediated inhibition of cutaneous wound healing. *J Clin Invest* 2002; **110**: 615.
21. Zanetta L, Marcus SG, Vasile J et al: Expression of von Willebrand factor, an endothelial cell marker, is up-regulated by angiogenesis factors: a potential method for objective assessment of tumor angiogenesis. *Int J Cancer* 2000; **85**: 281.
22. Dodge-Khatami A, Backer CL, Holinger LD et al: Healing of a free tracheal autograft is enhanced by topical vascular endothelial growth factor in an experimental rabbit model. *J Thorac Cardiovasc Surg* 2001; **122**: 554.
23. Hassan JM, Pope JC 4th, Revelo P et al: The role of postoperative testosterone in repair of iatrogenic hypospadias in rabbits. *J Pediatr Urol* 2006; **2**: 329.