

Limitations of Extracorporeal Shockwave Lithotripsy for Lower Caliceal Stones: Anatomic Insight*

FRANCISCO J.B. SAMPAIO, M.D., PH.D., and AFONSO H.M. ARAGAO, M.D.

ABSTRACT

In addition to gravity-dependent position, we suppose that other particular anatomic features may be important in the retention of stone debris in lower calices after extracorporeal shockwave lithotripsy (SWL). We analyzed the inferior-pole collecting system anatomy in 146 three-dimensional polyester resin corrosion endocasts of the pelvicaliceal system. In 74% of the cases, there was an angle of greater than 90° formed between the lower infundibulum and the renal pelvis, and in 26%, the angle was 90° or less. In 60%, there was a lower infundibulum 4 mm or larger in diameter. The inferior pole was drained by multiple calices disposed in two rows in 57% of the cases and by one midline caliceal infundibulum in 43%. We believe that the physician must appreciate these anatomic features when considering SWL to treat calculi located in lower calices.

INTRODUCTION

NOWADAYS, EXTRACORPOREAL SHOCKWAVE LITHOTRIPSY (SWL) is the method of choice for the treatment of kidney stones and appears to be safe, efficient, and cost effective in the majority of cases.^{1,2} However, the procedure is not uniformly effective for all types of kidney stones.³ There is a consensus that the lowest success rate is in the complete clearance of stones located in the lower calices.³⁻⁹ The main factor presumed to be the cause of that low success rate is the gravity-dependent position of these calices.⁴⁻⁸ Undoubtedly, the position of inferior-pole calices plays an important role in hampering the passage of fragments. Nevertheless, it remains unknown why some patients clear lower caliceal stones well, whereas others have insufficient or no discharge of inferior-pole fragments for long periods after SWL.

We proposed that in addition to gravity-dependent position, anatomic features such as the angle formed between the lower infundibulum and the renal pelvis, the lower infundibula diam-

eters, and the spatial distribution of the lower calices are important in the retention of fragments after SWL performed to treat stones located in lower calices.^{10,11}

MATERIAL AND METHODS

We studied 146 three-dimensional polyester resin corrosion endocasts of the kidney collecting system obtained from 73 fresh adult cadavers of both sexes who died of causes not related to the urinary tract. The endocasts were produced using the technique described in previous papers.^{10,12} Because polyester resin polymerizes on addition of a catalyst, there is no shrinkage on setting, enabling measurements of the diameters and angles that existed *in vivo*.^{10,12} Thus, the endocasts of pelvicaliceal system enabled analysis of the angle formed between the lower infundibulum and the renal pelvis, the lower infundibular diameters, and the spatial distribution of the lower calices.

Department of Anatomy, State University of Rio de Janeiro, Rio de Janeiro, Brazil

*Supported by grant (CNPq-Brazil), 50.1342/91-5/BM-FV from the National Council of Scientific and Technological Development. Presented in part at the Eleventh World Congress on Endourology and ESWL, Florence, Italy, October 1993.

RESULTS AND DISCUSSION

Retention of stone fragments in the lower calices is an important shortcoming of SWL, and the elevated percentage of residual fragments in these calices appears to be the main negative factor in the rate of success.³⁻⁸ In an attempt to reverse this elevated rate of residual fragments, different measures have been proposed, such as treatment in the Trendelenburg position, inversion therapy (patients in a head-down position) with or without forced diuresis after SWL, and direct irrigation of the lower calices.⁸

Our anatomic findings suggest that retention of "passable stone fragments" (4 mm in diameter or less) in the inferior pole might be a consequence not only of the gravity-dependent position of lower calices but also of particular anatomic features of the inferior-pole collecting system. In many cases, the spatial anatomy of this region appears definitely to be an important factor in the evacuation of stones debris.

Angle Between Lower Infundibulum and Renal Pelvis

In 108 of the 146 casts (74%), an angle of greater than 90° was formed between the lower infundibulum and the renal pelvis (Fig. 1). In the other 38 casts, the angle was close to or smaller than 90° (Fig. 2).

We understood that the infundibular angle is of utmost importance in inferior pole drainage. Patients in whom this angle is greater than 90° should have better drainage, and consequently eliminate stone debris more easily, than those with more acute angle. When the patient is in an orthostatic position, the kidneys whose inferior poles are drained by infundibula presenting angles of greater than 90° will have reasonable drainage (Fig. 3). Contrariwise, the inferior poles drained by infundibula presenting angles smaller than 90° will have poor drainage when the patient is in the orthostatic position (Fig. 4).

Lower calices drained by infundibula that form angles of greater than 90° with the renal pelvis will achieve a gravity-fa-

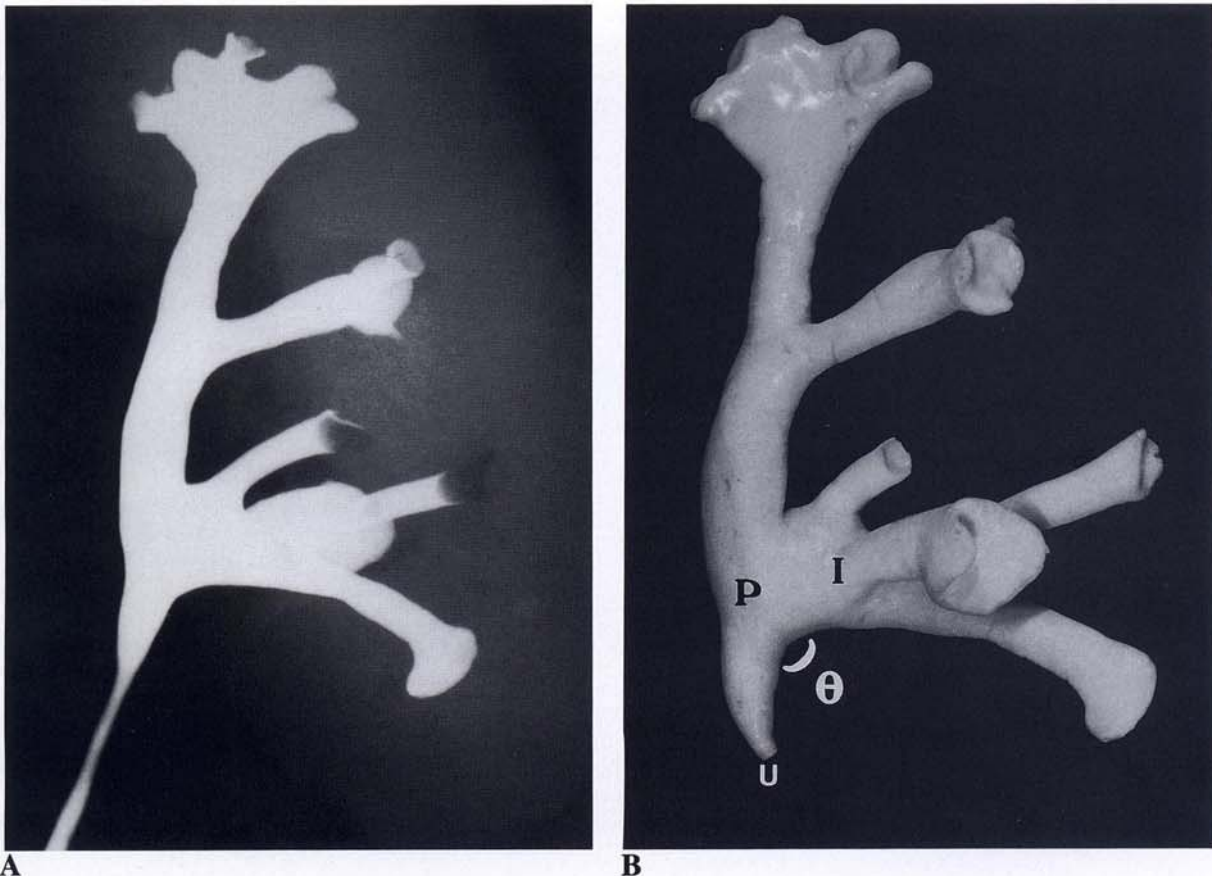


FIG. 1. In some kidneys, angle of lower infundibulum with renal pelvis exceeds 90°. A. Retrograde pyelogram of left kidney shows angle of greater than 90° between lower infundibulum and renal pelvis. B. Three-dimensional pelviocaliceal endocast from same kidney reveals angle (θ) of 115° between lower infundibulum (I) and renal pelvis (P). u = ureter.

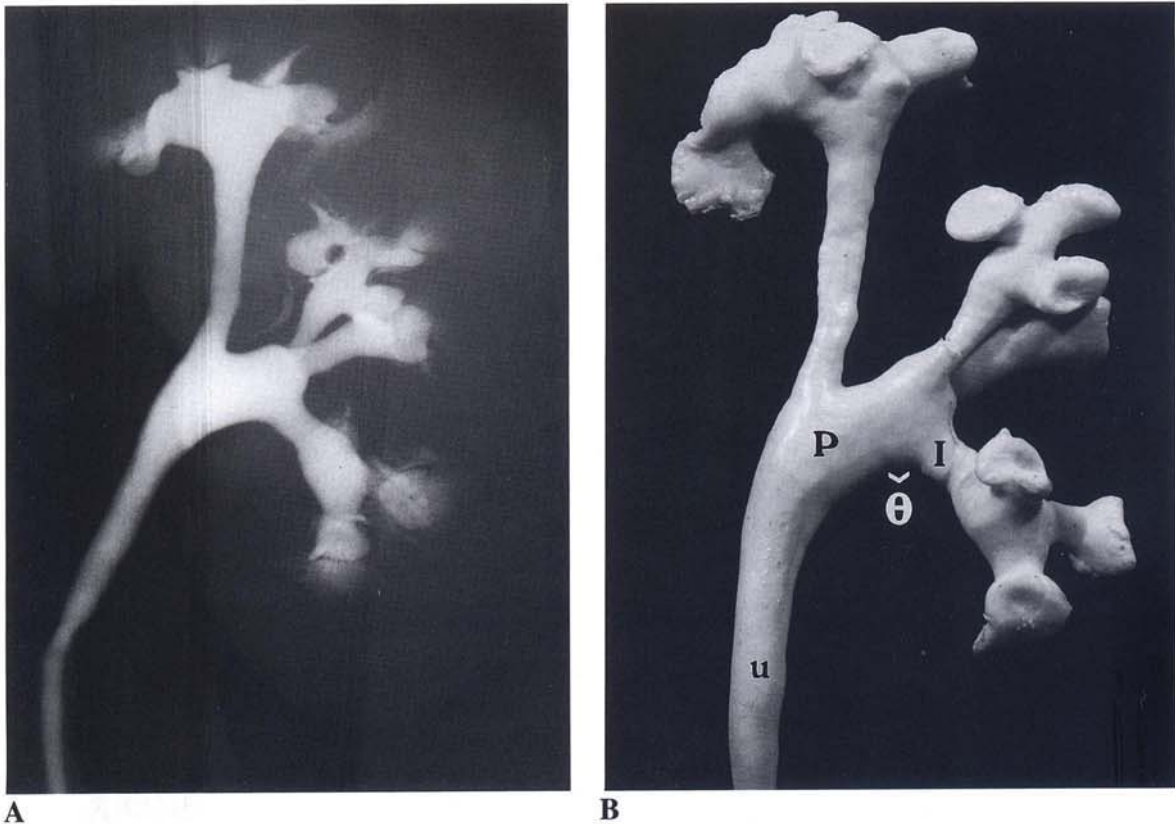


FIG. 2. In other kidneys, infundibular-renal pelvic angle is more acute. A. Retrograde pyelogram of left kidney shows angle smaller than 90° between lower infundibulum and renal pelvis. B. Three-dimensional pelvicaliceal endocast from same kidney; $\theta = 60^\circ$. For Key, see Figure 1.

avorable situation (good drainage) when the patient lies in an opposite lateral position (Fig. 5A). In these cases, after SWL, the physician may advise the patient to sleep in this position in order to enhance the elimination of fragments from the lower calices. On the other hand, the lower calices drained by infundibula that form angles close to or smaller than 90° with the renal pelvis will remain in a gravity-dependent situation (poor drainage) even when the patient rests in an opposite lateral position (Fig. 5B).

A possible solution was studied in patients with stone debris in lower calices after SWL.⁶ The findings suggested that multiple sessions of inversion therapy (patients in a 60° to 75° head-down position) associated with hydration and dorsal percussion could have a beneficial role in the management of such patients. Other physicians also used active upside-down physical activity together with dorsal vibration massage to facilitate the elimination of stone fragments from lower calices.¹³ Although those authors had not considered the lower infundibular angle, we think that the subject is important. Based on our anatomic findings, we inferred that in patients with an angle of greater than 90° between the lower infundibulum and the renal pelvis (Figs. 1 and 3), postural drainage with the patient in the opposite lat-

eral position (Fig. 5A) will play the same beneficial role as that of a 60° to 75° head-down position,^{10,11} with much less suffering.

Infundibular Diameter

We believe that the infundibular diameters of the lower calices may also play an important role in SWL. In 88 of the 146 casts (60%), we found inferior-pole infundibula 4 mm or larger in diameter (Fig. 6A). In the remaining 58 casts, the lower calices presented at least one infundibulum smaller than 4 mm (Fig. 6B). These smaller infundibula will certainly make the spontaneous discharge of presumed passable stone debris (often defined as fragments 4 mm in diameter or less) difficult after SWL. On the contrary, a lower-pole infundibulum with a suitable diameter (greater than 4 mm) should facilitate the elimination of such fragments.

Spatial Distribution of Lower Calices

Many authors affirm that there usually is only one caliceal infundibulum draining each pole.¹⁴⁻¹⁶ Nevertheless, we found in 83 of the 146 casts (57%) an inferior pole drained by multiple

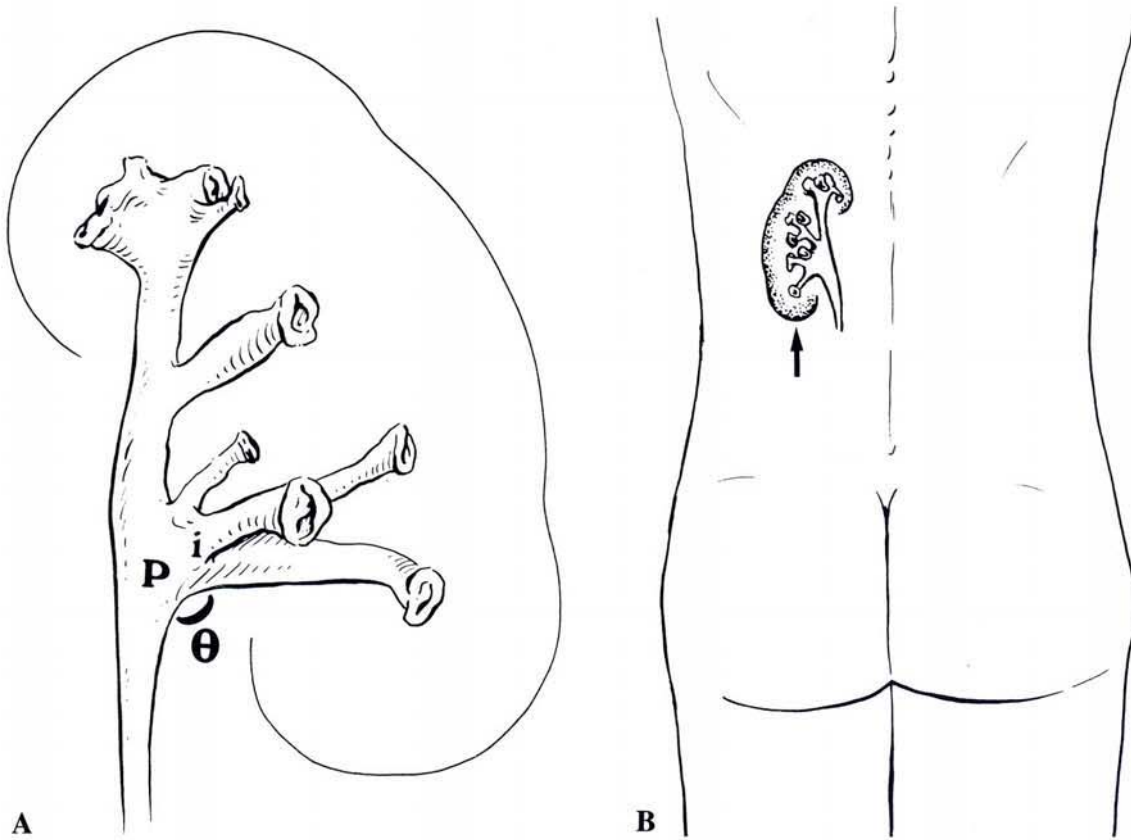


FIG. 3. Good drainage with infundibular–renal pelvic angle greater than 90° . A. Schematic drawing of endocast shown in Figure 1B. B. When patient with this kidney is in orthostatic position, inferior pole (arrow) can have reasonable drainage. For Key, see Figure 1.

(three to seven) calices^{10–12} which were disposed in two rows, anterior and posterior (Fig. 7A). In the remaining 63 casts, the inferior pole was drained by a single midline caliceal infundibulum receiving two or three fused papillae (Fig. 7B). It is conceivable that an inferior pole with multiple calices (Fig. 7A) has poorer drainage and, consequently, less possibility of eliminating stone fragments than an inferior pole drained by only one midline infundibulum receiving fused calices (Fig. 7B).

Clinical Application

Taking into account these anatomic details, in patients with stones in the lower calices, a radiologic study before SWL must be done with anteroposterior, lateral, and oblique films to determine accurately the anatomy of the inferior-pole collecting system. In some cases, the use of CT or magnetic resonance imaging may be helpful to ascertain the precise spatial caliceal anatomy.¹⁷

On the basis of these careful imaging studies, the physician may detect the cases in which, associated with the gravity-de-

pendent position of the lower calices, there are other anatomic features (infundibular angle close to or smaller than 90° ; infundibula smaller than 4 mm in diameter; multiple calices) that may inhibit the evacuation of stone fragments. The physician can then advise the patients that they have a greater risk for fragment retention after SWL. In these cases, percutaneous procedures may be proposed to treat stones in such lower calices.^{10,11} We believe that the association of at least two of these anatomic restrictions is sufficient to contraindicate extracorporeal therapy. Recent studies have been demonstrated significantly better stone-free rates, associated with low morbidity, for percutaneous nephrolithotomy for all sizes of lower-pole calculi compared with SWL.^{3,18}

It is important to remember the limitations of SWL for various stone situations, including the particular anatomic difficulties that we have described and discussed. It is not rational to perform multiple sessions of SWL to observe what will occur with stones or fragments.¹⁹ In the same way, it is not reasonable to offer the patient an elective procedure that can achieve a rate of good results of only 60%.

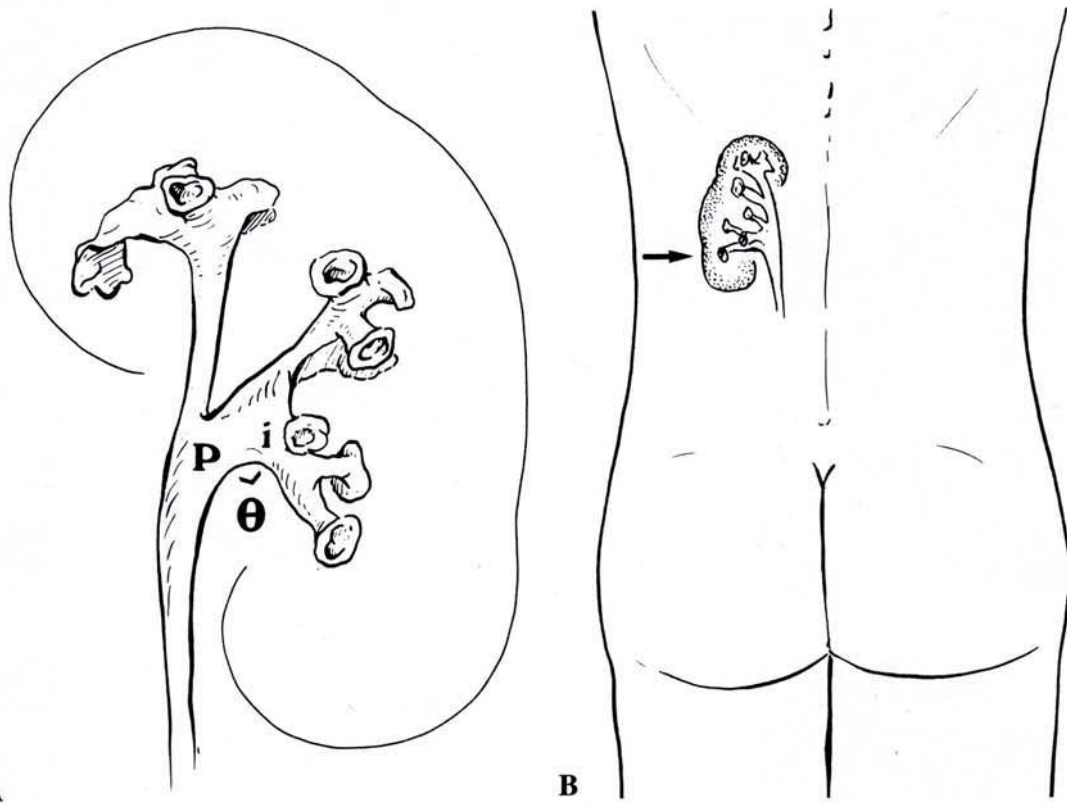


FIG. 4. More acute angle impedes drainage. A. Schematic drawing of endocast shown in Figure 2B. B. When patient with this kidney is in orthostatic position, inferior pole (arrow) has poor drainage. For Key, see Figure 1.

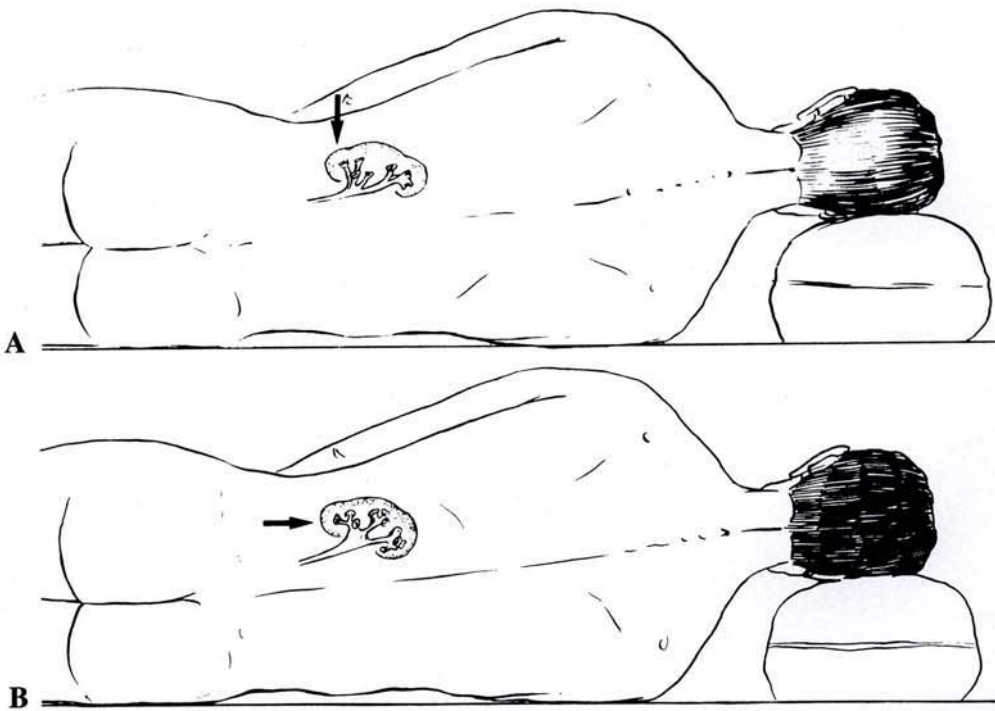


FIG. 5. Improving fragment clearance according to θ . A. Lower calices drained by infundibulum with θ greater than 90° achieve a gravity-favorable situation (good drainage) when patient is in opposite lateral position (arrow). B. Lower calices drained by infundibulum with θ smaller than 90° remain in a gravity-dependent situation (poor drainage) even when patient is in opposite lateral position (arrow). Inversion therapy may be helpful.

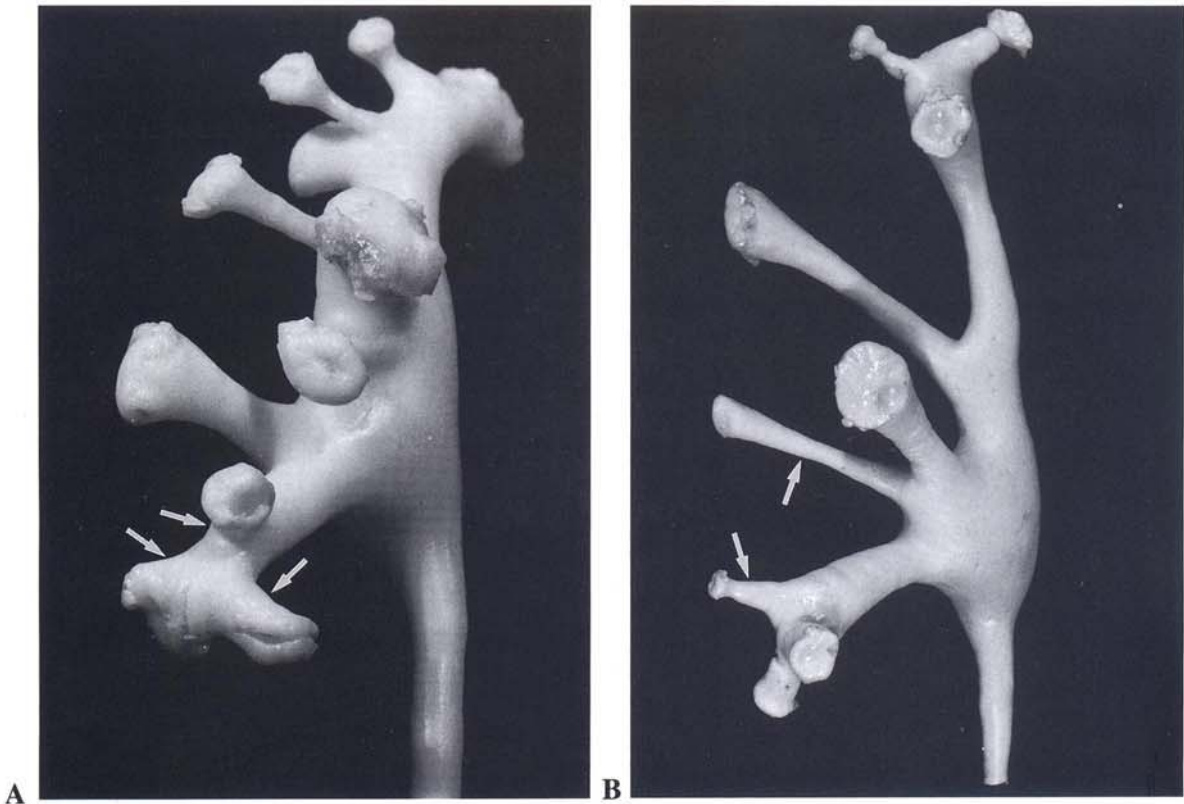


FIG. 6.

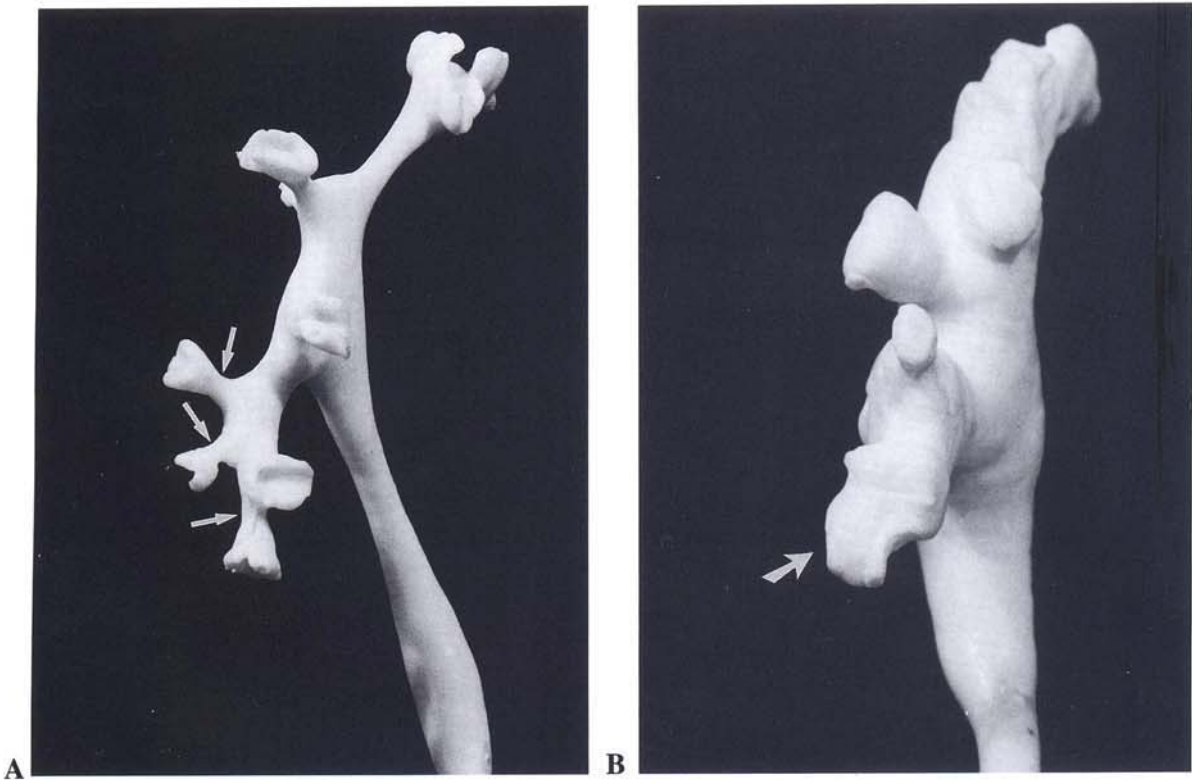


FIG. 7.

REFERENCES

1. Drach GW, Dretler S, Fair W, et al: Report of the United States Cooperative Study of Extracorporeal Shock Wave Lithotripsy. *J Urol* 1986;135:1127
2. Rassweiler J, Köhrmann KU, Potempa D, et al: Extracorporeal shock wave lithotripsy for renal calculi: current status and future aspects. *Minim Invas Ther* 1992;1:141
3. Siegel YI, Lingeman JE, Steele B: The management of lower pole nephrolithiasis: meta-analysis (abstract 21). *J Urol* 1993;149:219A
4. McCullough DL: Extracorporeal shock wave lithotripsy and residual stone fragments in lower calices (letter). *J Urol* 1989;141:140
5. McDougall EM, Denstedt JD, Brown RD, et al: Comparison of extracorporeal shock wave lithotripsy and percutaneous nephrolithotomy for the treatment of renal calculi in lower pole calices. *J Endourol* 1989;3:265
6. Brownlee N, Foster M, Griffith DP, et al: Controlled inversion therapy: an adjunct to the elimination of gravity-dependent fragments following extracorporeal shock wave lithotripsy. *J Urol* 1990;143:1096
7. Graff J, Diederichs W, Schulze H: Long-term follow-up in 1,003 ESWL patients. *J Urol* 1988;140:479
8. Nicely ER, Maggio MI, Kuhn EJ: The use of a cystoscopically placed cobra catheter for directed irrigation of lower pole caliceal stones during extracorporeal shock wave lithotripsy. *J Urol* 1992;148:1036
9. Lingeman JE, Coury TA, Newman DM, et al: Comparison of results and morbidity of percutaneous nephrostolithotomy and extracorporeal shock wave lithotripsy. *J Urol* 1987;138:485
10. Sampaio FJB, Aragao AHM: Inferior pole collecting system anatomy: its probable role in extracorporeal shock wave lithotripsy. *J Urol* 1992;147:322
11. Sampaio FJB: Spatial anatomy of the lower calices: importance in extracorporeal shock wave lithotripsy. In: *Renal Anatomy Applied to Urology, Endourology, and Interventional Radiology*. New York: Thieme Medical Publishers, 1993, pp 16–22
12. Sampaio FJB, Mandarim-de-Lacerda CA: 3-Dimensional and radiological pelvicaliceal anatomy for endourology. *J Urol* 1988;140:1352
13. Tolon M, Miroglu H, Tolon J, et al: A report on extracorporeal shock wave lithotripsy results on 1,569 renal units in an outpatient clinic. *J Urol* 1991;145:695
14. Coleman CC: Percutaneous nephrostomy: renal anatomy. In: *Atlas of Endourology*. Chicago: Year Book Medical Publishers, 1987, pp 13–32
15. Graves FT: The anatomy of the pelvis and ureter. In: *Anatomical Studies for Renal and Intrarenal Surgery*. Bristol: Wright, 1986, pp 72–85
16. Kaye KW, Reinke DB: Detailed caliceal anatomy for endourology. *J Urol* 1984;132:1085
17. Heynes CF, van Gelderen FC: 3-Dimensional imaging of the pelvicaliceal system by computerized tomographic reconstruction. *J Urol* 1990;144:1335
18. Lingeman JE, Siegel YI, Steele B: Percutaneous nephrostolithotomy for the management of nonstaghorn lower pole nephrolithiasis (abstract 408). *J Urol* 1993;149:315A
19. Smith AD: Stone management in the '90s. *AUA Today*, November 1990;3:16

Address reprint requests to:
 Francisco J.B. Sampaio, MD, PhD
 Biomedical Center
 State University of Rio de Janeiro
 CAIXA POSTAL No. 46503
 Rio de Janeiro—R.J.—Brazil
 20562-970

FIG. 6. Diameter of infundibula may affect fragment clearance. A. Oblique-anterior view of pelvicaliceal endocast from right kidney shows inferior pole drained by caliceal infundibula greater than 4 mm in diameter (arrows). B. Oblique-anterior view of pelvicaliceal endocast from right kidney shows inferior pole drained by caliceal infundibula smaller than 4 mm in diameter (arrows). Some "passable" fragments may be trapped in kidney of this type.

FIG. 7. Differences in spatial distribution of calices may affect clearance. A. Oblique-anterior view of pelvicaliceal endocast from right kidney shows inferior pole drained by multiple calices. There are calices presenting infundibula smaller than 4 mm in diameter (arrows); these may not be cleared of fragments readily. B. Lateral view of pelvicaliceal endocast from right kidney shows inferior pole drained by single midline caliceal infundibulum (arrow). Clearance of fragments from this kidney is likely to be better.